Original Article

Treatment of Long Segment Anterior Urethral Stricture by Dorsal Free Graft Urethroplasty by Ventral Sagittal Urethrotomy Approach

***Md. Zahid Hussain[1], Md. Suhel Al Mujahid Reza[2], Md. Abdul Alim[3], A. S. M. Humayun Kabir[4], Md. Mofiz Uddin[5], Mohammad Kamruzzaman[6]**

Abstract

Introduction: Long segment anterior urethral stricture involving the penile and bulbar urethra, is a common urological problem in Bangladesh and South Asian subcontinent. It is really difficult and challenging to manage. It is a feasibility study of applying a dorsal free graft to treat urethral stricture by the ventral sagittal urethrotomy approach without mobilizing the urethra. **Methodology:** In this prospective multicenter observational study, 50 cases of long segment or multiple anterior urethral strictures were studied over a period of one year from May 2005 to May 2006. All patients were treated by a full-thickness preputial or distal penile skin graft. The urethras were not separated from the corporal bodies and were opened ventrally in the midline over the stricture. The floor of the urethra was incised, and an elliptical raw area was created over the tunica on which graft skin was secured. The urethras were re-tabularized in one stage. **Results:** After a follow-up of 12 months, 1 recurrence developed and required optical internal urethrotomy (OIU). **Conclusion:** The ventral sagittal urethrotomy approach for long segment or multiple anterior urethral strictures by dorsal free graft urethroplasty is not only feasible and successful, but is also easy to perform.

Keywords: Dorsal inlay urethroplasty, ventral sagittal urethrotomy, anterior urethral stricture repair.

Abbreviations and Acronyms:

RGU & MCU = Retrograde Urethrogram and Micturating Cystourethrogram, BXO = Balanitis Xerotica Obliterans, Sec = Second, BMG = Buccal mucosal graft, OIU: Optical Internal Urethrotomy.

1. Associate Professor (Urology), Khulna Specialized Hospital, Khulna, Bangladesh
2. Associate Professor (Urology), Tangail Medical College, Tangail, Bangladesh
3. Associate Professor (Urology), M A G Osmani Medical College, Sylhet, Bangladesh
4. Assistant Professor (Urology), Khulna Specialized Hospital, Khulna, Bangladesh
5. Junior Consultant (Urology), Khulna Specialized Hospital, Khulna, Bangladesh
6. Junior Consultant (Urology), Khulna Specialized Hospital, Khulna, Bangladesh

***Address of Correspondence:** Dr. Md. Zahid Hussain, Associate Professor, Department of Urology, Khulna Specialized Hospital, Khulna. E-mail address: zahidbapy@yahoo.com.

Introduction

The traditional treatment of urethral stricture is urethral dilatation or urethrotomy [1]. Another modality of treatment for stricture urethra is urethroplasty. It may be anastomotic or substitution type. Anastomotic urethroplasty is achieved by excision of stricture segment and end to end spatulated anastomosis. It is curative for short segment (<2 cm) bulbar urethral stricture. It is not applicable for penile urethra because it shortens penile urethra which may interfere erection of penis later. Urethroplasty also be done by substitution of graft or flap. Traditionally, vascularized local skin flaps have been the most popular form of substitution urethroplasty in single stage or

staged procedures, but these are prone to late complications because of ballooning and diverticula formation, causing stasis of urine and leading to skin excoriation [1]. Free grafts of full-thickness penile or preputial skin used as ventral patch or tube have been in vogue for several decades, but are prone to shrinkage, leading to repeated stricture or diverticulum formation. Buccal mucosa used as above has recently become popular because of the ease of harvesting but has the same drawback [2]. Recently, dorsal free graft urethroplasty by mobilizing the urethra and incising the stricture dorsally has gained popularity, as the graft on the corporal bodies prevents ballooning [3, 4].

We describe a technique of laying open the stricture ventrally and then incising the urethra dorsally without mobilizing it to expose the tunica albuginea for free skin graft followed by re-tubularization of the urethra, with good results in long and multiple strictures in one stage.

Methods

In this prospective multicenter study of surgical repair of long anterior urethral stricture (stricture size ≥2 cm long) performed in Dhaka Medical College Hospital, Dhaka, Bangladesh, Bangabandhu Sheikh Mujib Medical University, Dhaka, Bangladesh and Comfort Hospital, Dhaka, Bangladesh from May 2005 to May 2006. A total of 50 patients were selected for this study. Operations were performed by different urologist. The etiology of the stricture was inflammatory 19 patients (38%), iatrogenic 12 patients (24%), post-traumatic 8 patients (16%), BXO 5 patients (10%), and unknown in 6 patients (12%). The location of urethral stricture was bulbar in 27 patients (54%), penile in 9 patients (18%), bulbo-penile in 8 patients (16%) and peno-meatal in 6 patients (12%). The inclusion criteria were patients with ≥2 cm long anterior urethral strictures who were physically and mentally fit for surgery. We included patients who presented for primary consultation as well as those patients with previous failed repair. The exclusion criteria were, patient with <2 cm anterior urethral stricture; patient with unhealthy genital skin like Balanitis Xerotica Obliterans (BXO) involving penile shaft skin, malignancy, diabetes, bladder neck stenosis / hypertrophy, benign enlargement of prostate, neuropathic bladder, history of cerebro-vascular accident, associated posterior urethral stricture ,patient who were unwilling or unable to undergo surgery or incomplete patient records.

All patients were evaluated by history and physical examinations. A detail questionnaire was completed which included the patient's age, duration of disease, number of previous procedure or operations performed upon the patient for stricture urethra. Enquiry was made for the cause of the stricture in every case. Careful local examination was done to identify meatal stenosis. All patients were further evaluated by urine culture, uroflometry, residual urine measurement, RGU & MCU. The follow up records were also reviewed for recurrent stricture, fistula, urethral diverticulum, hair growth, meatal stenosis, chordee formation and infection.

Surgical technique

Following general or spinal anesthesia, patient was placed in supine or lithotomy position according to the location of the stricture. A 3-0 polypropyline traction suture was placed in the glans. The urethra was exposed at the site of stricture through a ventral midline incision. The stricture segment was split open ventrally over a bougie and the urethra was laid open for about 1 to 2 cm both proximally and distally into the healthy urethra. The full thickness of the dorsal wall of the urethra was then incised

in the midline over the stricture and for about 1 to 2 cm both proximally and distally into the healthy urethra to expose tunica albuginea. The margins of the incised dorsal urethra were dissected from the tunica albuginea by sharp dissection with the edge of a No-15 blade without lifting the two halves of the bisected urethra (Fig.1.A). This provides an adequate elliptical raw area up to 2 cm wide, over the tunica albuginea, between the edges of the dorsal wall of the urethra. The incised dorsal free margins of the urethra were anchored to the tunica albuginea by interrupted sutures using 5-0 polyglactin. Two cm wide sub-coronal or distal penile shaft skin was harvested by two parallel circumferential sub-coronal incisions and the length of the graft was determined according to the length of the urethral defects (Fig.1B, 1 C).

Graft tissue was placed in a pot of normal saline and was carefully defatted by sharp scissors using 3 times magnifications. Then harvested full thickness free graft was placed over the raw area of the tunica albuginea between the incised margins of dorsal wall of the urethra and was anchored by 5-0 polyglactin sutures to the edges of the incised dorsal wall of the urethra, incorporating the underlying tunica albuginea. The graft was further anchored to the underlying tunica albuginea at several points to prevent dead space using 5-0 polyglactin (Fig.1 D, E). The urethra was re-tubularized by continuous 5-0 polyglactin sutures over a 16 Fr. Foley Catheter (Fig.1 F, G). Compression dressing was applied. If there is no complication patient was discharged after 7 days. The catheter was removed after 3 weeks. Uroflowmetry and RGU were performed in all cases after removal of catheter. Further follow up done at 3 months, 6 months and 1 year after operation. 3 Patients were asked to follow-up on regular basis.

Results

In this series, fifty cases of long and multiple anterior urethral strictures ranging from 2 to 10 cm (mean 6.22cm) were operated on between May 2005 to May 2006 with follow-up of 12 months. Out of 50 patients ,2 patient developed complications shown in table I.

Table I. Complications of operation among the subjects (n=50).

Complications	Frequency n (%)
Re-stricture	1 (2)
Wound infection	1 (2)

Total number of patients developed complications was 2 (4%). Patient with wound infection was kept in hospital for 20 days due to development of temporary urethra-cutaneous fistula after removal of catheter. It was resolved after re-catheterization for another 7 days. Cosmetic appearances of penis were acceptable and harvesting of skin from distal shaft of circumcised penis did not hamper erection.

Before operation, all patients had poor urine flow rete according to uroflowmetry report. Post-operative uroflowmetry report shown in table II.

Table II. Uroflowmetry result among the subjects (n=50).

Uroflowmetry result	Frequency n (%)
Good and average	48 (96)
Poor	2 (4)

Good and average flow rate is considered as success and poor flow rate as failure. After removal of catheter (21 days after operation), uroflowmetry showed good flow rate (Q Max >15 ml/sec) and average flow rate (Q Ave=10-15 ml/sec in 48 patient (96 %), and poor urinary flow rate (Q Ave <10ml/sec) in 2 patient (4 %). During third follow up visit (12

months after operation), Uroflowmetry showed similar result. Thus, the overall success rate was 96%.

RGU & and MCU done in all patients preoperatively to identify site/sites of stricture, length of stricture. Post-operative RGU &MCU done in all patient after removal of catheter and 12 months after operation. The result of post-operative RGU & MCCU shown in table III.

Table III. RGU & MCU results among the subjects (n=50).

Urethral caliber	Frequency n (%)
Normal	48 (96)
Poor caliber	2 (4)



Figure 1. A: Dorsal wall of the urethra before operation.

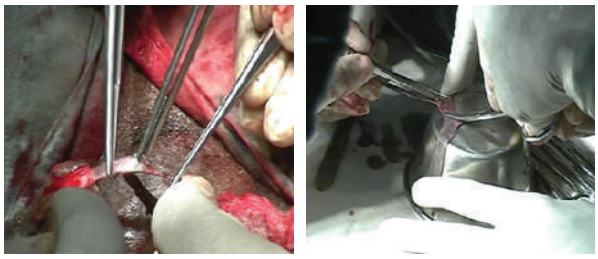

Figure 1. B & C: Harvesting of the skin from distal penile shaft dissected.



Figure 1. D: Anchoring of the graft.



Figure 1. E: Re-tubularization of the urethra.



Figure 1. F: After operation.

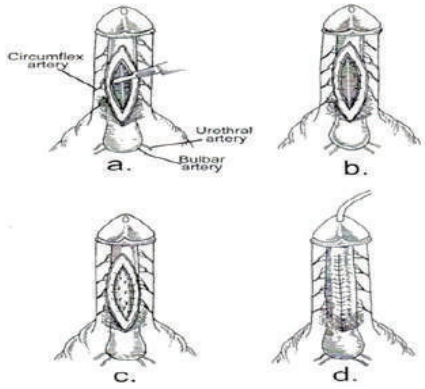

Figure 2: Steps of dorsal free graft urethroplasty.

a. Separation of margins of dorsal urethrotomy from corporal bodies
b. Securing of free margins to tunica albuginea
c. Fixation of dorsal free graft
d. Re-tabularization of urethra [3].

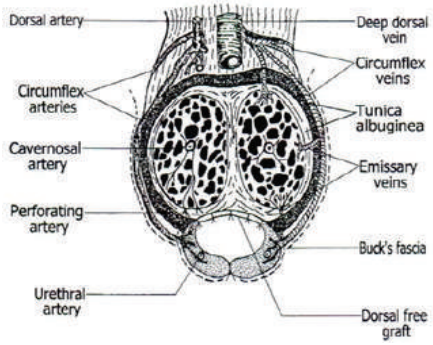

Figure 3: Cross-section of penis, dorsal free graft anchored [3].

Interpretation of RGU & MCU is good when report shows normal caliber urethra and good voiding study, average when report shows pseudodiverticulum or mild narrowing of urethra and poor when shows recurrence of stricture. In our study early success rate was 96% which persist more or less same 12 months after operation.

Discussion

The incidence of urethral stricture is increasing [1]. In this study penile or prepucial skin were substituted. They were intensely followed up for one year. In our study, age range of patient was 15 to 65 years. In series of Barbagli and colleagues, age range was 16 to 86 years [3]. In Iselin CE and Webster GD series, age range was 10 to 81 years and Asopa's series 16 to 54 years [4, 5].

In this study, most common site of stricture was bulbar urethra 54% (27). Most common length of stricture was 5 to 7 cm. In the series of Asopa and associates, length of the strictures ranged from 2-10 cm (mean 6 cm) [6]; in series of Barbagli and coworkers, it was 1.5 to 6 cm [3] and in series of Blum and colleagues, it was 3.5 to 10 cm long [7].

Most common cause of stricture was inflammatory (38 %). Whereas in series of Brannan and coworker's highest incidence of strictures were iatrogenic (31%), followed by inflammatory (21%) [8].

Again in series of Barbagli and coworkers, highest incidence of strictures were iatrogenic (60%), followed by inflammatory (16%) [3]. The cause of this statistical discrepancy may be the prompt effective antibiotic treatment of gonococcal urethritis and as a result it rarely progressed to gonococcal urethral stricture, but in the past, it was the main cause of inflammatory strictures [9].

Post-operative complications in our study were wound infection and temporary urethrocutaneous fistula (2%), and recurrent stricture (2%). Mean hospital stay was 9±2.43 days. Harvesting of distal shaft penile skin does not hamper erection and cosmetic appearance of external genitalia were acceptable in our series. Urine flow rate was >15ml/s in 96% of cases. In a series of dorsal free graft urethroplasty by ventral sagittal urethrotomy approach described by Asopa and colleagues, 8.3% cases developed temporary urethrocutaneous fistula which was resolved by additional catheterization for another 2 weeks. One patient (8.3%) developed recurrent stricture and was controlled by dilatation. Urinary flow rate was >15ml/s after 1 year follow up in all cases and obstructive symptoms were not complained during follow up [6]. Iselin and coworkers showed 97% success rate of dorsal free graft urethroplasty for bulbar urethral strictures after a median follow up of 19 months and in their series only one patient who had undergone 6 previous urethral procedures, had symptomatic stricture recurrence after 1 year, which was under dilatation and required no further treatment [4].

In series of Barbagli, all patients showed satisfactory urine flow rate >14ml/s after mean follow up of 35.5 months. Though 5 patients developed temporary anastomotic fistula which were resolved after 1 week of further catheterization [3].

Temporary urethrocutaneous fistula were detected in 3 cases out of 20 cases in another series, but they all resolved spontaneously and only one patient developed short segment recurrent stricture which was successfully treated by optical urethrotomy [10]. Our study is comparable with the series of other centers [4, 6, 10].

Webster and coworkers reported development of chordee during erection in 1 patient who

underwent free full thickness skin graft urethroplasty for penile urethral strictures [5]. Again Iselin and colleagues, Webster and associates restricted the use of dorsal free graft to bulbar urethral stricture because of concern that the inelasticity of the graft may result in erectile chordee [4, 5]. But the fear has proved unfounded, because graft survival and good healing without stricture have been the rule in all locations, provided adequate healthy tissue is present for the graft bed [8]. Dorsal placement of the graft is not associated with chordee [3, 6]. Barbagli and coworkers performed dorsal free graft urethroplasty in stricture of penile urethra and observed no such complications [3]. In our serise also, no one had developed any chordee. Dorsal free graft urethroplasty has a high early success rate of 97% in case of bulbar urethral stricture after average 19 months follow up [4, 5]. In our series success rate was almost 96%.

The length of the stricture is not been a limiting factor for dorsal free graft urethroplasty since preputial and penile shaft skin is pliable and redundant [3, 4]. Even when the patient is circumcised, there usually has redundant distal penile skin available for repair of any length of strictures [11].

Conclusion:

Based on the previous studies and our experience we can recommend dorsal free graft urethroplasty by local penile skin substitution is a good technique for management of long segment anterior urethral stricture. It is easy to perform because the urethra is not mobilized. The sizing of the graft is accurate and hence pooling of urine and semen is minimized. The risk to hamper the blood supply of the two halves of the bivalved urethra is less because it gets adequate blood supply from the corpora and from the circumflex arteries.

References

1. Andrich DE, Mundy AR. Urethral Stricture and their surgical management. Br J Urol 2000; 86: 571-580.
2. Venn SN, and Mundy AR: Early experience with the use of buccal mucosa for substitution urethroplasty. Br J Urol 81: 738-740, 1998.
3. Barbagli G, Selli C, Tosto A, et al: Dorsal-free graft ure- throplasty. J Urol 155: 123-126, 1996.
4. Iselin CE, and Webster GD: Dorsal onlay graft urethro- plasty for repair of bulbar urethral stricture. J Urol 161: 815- 818, 1999.
5. Webster GD, Koefoot RB, Sihelnik SA.Urethroplasty management in 100 cases of urethral stricture. A rational for procedure selection. J Urol 1985; 134: 892-898.
6. Asopa HS, Garg M, Singhal GG, et al. Dorsal free graft urethroplasty for urethral sitricture by ventral sagittal urethrotomy approach. J Urol 2001; 58: 657-659.
7. Blum JA, Feeney MJ, Howe GE, et al. Skin patch urethroplasty, 5 year follow up. J Urol 1982; 127:909.
8. Brannan W, Ochsner MG, Fuselier HA, et al. Free full thickness skin graft urethroplasty for urethral stricture, experience with 66 patients. J Urol 1976;115: 667-680.
9. Jordan GH, Schlossberg SM, Devine CJ. Surgery of the penis and urethra. In: Campbell's urology, Vol-3, 7th edition edited by Walsh PC, Vaugha DE Jr, Wein AJ; W.B. Saunders, Philadelphia. 1998; pp. 3317-3359.
10. McAninch JW. Disorders of the penis and male urethra, in Smith's general urology. Edited by Tanagho EA, McAninch JW. 5th l international edition, McGraw-Hill Co, Philadelphia, 2000; pp.670-672.
11. Devine PC, Sakati lA, Poutasse EF, et al . One stage urethroplasty, repair of urethral strictures with a free full thickness patch of skin. J urol I968 ; 99:19l-193.