Original Article

Evaluation of Performance of Exfoliative Cytology of Voided Urine in the Diagnosis of Urinary Bladder Mass

Professor Mohammed Shahed Ali Jinnah[1], *Md. Shahrior Nahid[2], Professor Abdul Khaleque Akond[3], Professor Enamul Kabir[4]

Abstract

Background: Urinary Bladder cancer is the fourth most common neoplasm of men. Among the types of malignancy, an average of 90% to 95% of malignant bladder tumors are papillary urothelial carcinoma, not otherwise specified. Diagnosis is made based on the cystoscopy features, tumor biopsy, and urine cytology. Exfoliative cytology of urine is a harmless noninvasive investigative tool for the detection of urothelial tumors and for follow-up of treated bladder cancer patients. The purpose of the present study is to evaluate the performance of exfoliative cytology of vided urine in the diagnosis of urinary bladder mass. **Methods:** A total of 100 cases age ranging from 16 years to 110 years were included in this study which were clinically suggestive and cystoscopically and/ or sonographically suspected cases of bladder mass. For cytological examination, morning's 2nd voided urine was collected, processed, and directly smeared on albuminized glass slides. The slides were fixed in 95% ethyl alcohol and then stained with the Papanicolaou method and examined under a light microscope. Subsequently, Formalin-fixed paraffin-embedded (FFPE) tissue blocks were prepared from biopsy samples and stained with hematoxylin and eosin stain. Then examined under the light microscope. All data were recorded in a preformatted data sheet. Relevant data were analyzed for calculation of accuracy, sensitivity, specificity, positive predictive value, and negative predictive value. **Results:** In the present study, positive cytological diagnoses for malignancy were made in 73 (73%) cases and negative in 27 (27%) cases. Subsequently, histopathological diagnoses of 100 cases were correlated and found papillary urothelial carcinoma in 76 (76%) cases followed by adenocarcinoma, metastatic squamous cell carcinoma, leiomyosarcoma, and sarcoma botryoides 1 (1%) case in each. The rest of the cases were non-malignant inflammatory conditions. Regarding the grading of papillary urothelial carcinoma, 53 (53%) bladder tumors were of high grade and 23(23%) were of low grade. A 100% positive correlation was noted in the detection of high-grade papillary urothelial carcinoma, adenocarcinoma, metastatic squamous cell carcinoma, and leiomyosarcoma. Only one case of sarcoma botryoides could not be detected by urine cytology. Of 23 low-grade papillary urothelial carcinoma, 15 (65%) were cytologically positive for malignancy and 08 (35%) were cytologically negative. Among the total 80 cases of malignant tumors, 55 were invasive in nature. All the invasive tumors showed positive urine cytology except sarcoma botryoides. It was found that the sensitivity and specificity of exfoliative urine cytology in the diagnosis of urinary bladder tumor were 88.8% and 90.0% respectively for all tumors. The positive predictive value (PPV) of exfoliative urine cytology in predicting urinary bladder tumor among the test-positive subjects was 97.3% and the negative predictive value (NPV) among the test-negative subjects was 66.7%. The percentage of false negatives was 11.3% and false positives was 10%. The overall accuracy of the diagnosis of urinary bladder tumor by exfoliative urine cytology was 89%. **Conclusion:** Cytologic studies of voided urine are useful for diagnosing of urothelial tumors. In resource-poor settings like ours, urine cytology can be used as a simple non-invasive diagnostic tool for the detection of urinary bladder tumors.

Keywords: Urinary bladder mass, Urine cytology.

1. Professor of Pathology, Director, National Institute of Laboratory Medicine and Referral Center, Sher-E-Bangla Nagar, Dhaka, Bangladesh.
2. Resident Medical Officer, Department of Pathology, National Institute of Laboratory Medicine and Referral Centre (NILMRC), Sher-E-Bangla Nagar, Dhaka, Bangladesh.
3. Ex-Professor and Head, Department of Pathology, Dhaka Medical College, Dhaka, Bangladesh.
4. Professor and Head, Department of Pathology, Popular Medical College, Dhanmondi, Dhaka, Bangladesh.
***Address of Correspondence:** Dr. Md. Shahrior Nahid, Resident Medical Officer, Department of Pathology, National Institute of Laboratory Medicine and Referral Centre (NILMRC), Sher-E-Bangla Nagar, Dhaka-1207. Email: shahrior.nahid@gmail.com.

Introduction

Urinary bladder cancer is the fourth most common neoplasm of men in North America [1]. It is also the 8th most common cancer in females in the United States of America (USA) [2]. The median age of diagnosis is 65 years [3]. The incidence of bladder cancer is gradually increasing [4]. Among the types of malignancy, an average of 90% to 95% of malignant bladder tumors are papillary urothelial carcinoma, not otherwise specified and the remaining 5% to 10% comprise mesenchymal neoplasms and epithelial tumors of other types including squamous cell carcinoma, sarcoma botryoides, leiomyosarcoma [5]. The common risk factors for bladder cancer include cigarette smoking, occupational exposure to polycyclic aromatic hydrocarbons, diesel smoke, aromatic amines, arsenic poisoning, abuse of phenacetin-containing analgesics, inflammation of the bladder, cyclophosphamide, radiotherapy for uterine cancer, and Schistosomiasis infection. Cigarette smoking is the main cause of bladder cancer and accounts for about 50% of cases in developed countries [6, 7]. Clinically, the most common presenting symptom of bladder cancer is painless hematuria which occurs in about 85% of patients. The rest of the common symptoms are irritative voiding symptoms like urinary frequency, urgency, and dysuria [8]. The most invasive and metastatic bladder cancers are not derived from papillary lesions but from flat carcinoma in situ and related lesions. Many carcinomas in situ do not form any cystoscopic visible abnormalities at all. Diagnosis is made based on the cystoscopy features, tumor biopsy, and urine cytology [9]. Though exfoliative cytology of urine is not routinely practiced in our settings, it is a harmless noninvasive investigative tool for the detection of urothelial tumors and for follow-up of treated bladder cancer patients [10]. A few studies showed that urine cytology can detect cancer not only before it progresses to invasive disease but also long before its cystoscopic and radiographic recognition [11-13]. The present is designated to evaluate the accuracy, sensitivity, specificity, positive predictive value, and negative predictive value of urine cytology in the diagnosis of urinary bladder mass. It is of particular interest to see how a simple test can be helpful as one of the powerful diagnostic tools in the detection and diagnosis of different malignant tumors of the urinary bladder.

Methods

This cross-sectional observational study was carried out in the Department of Pathology, Sir Salimullah Medical College and Hospital (SSMCH), Dhaka, Bangladesh from July 2007 to April 2009. A total of 100 patients with clinical symptoms (including hematuria and other irritative voiding symptoms) and sonologically detected bladder mass were included in this study. A second voided urine sample was collected from each patient to get exfoliated cells without bacterial contamination. Samples were taken to the laboratory within three hours. Then 50ml urine of each sample was centrifuged for five minutes. The supernatant was decanted and pellets were directly

smeared on albumenized glass slides. The slides were then fixed in 95% ethanol. Papanicolaou stain was done in next day and examined in the light microscope. The smears undergoing cytological examination were diagnosed into six categories- a) Negative (no abnormal cells), b) Reactive Urothelial Cell (reactive atypia), c) Atypia or Atypical cell (alteration of cell morphology but benign in nature), d) Suspicious (strongly suggestive of malignancy but insufficient for an outright diagnosis), e) Positive or malignant cell present, f) Unsatisfactory (cellular content is extremely low for assessment) [14]. The first three categories were combined into one group as cytologically negative and the suspicious and positive groups were combined into a second group named cytologically positive [14]. Subsequently, biopsy materials were collected from all the 100 cases. Among them, 98 cases were transurethral resection of bladder tumor (TURBT) and two were cystectomy specimens. Fixation, gross examination, tissue processing, and staining were done according to standard protocol followed by the pathology department of Pathology, SSMC, Dhaka. Microscopically following features were described- 1) histologic type, 2) histologic grade, 3) architecture of the lesion, 4) pattern of growth, 5) depth of invasion, 6) extent of the lesion, 7) lymphovascular or perineural invasion, and 8) additional pathology if present. All the necessary data were recorded methodically and meticulously in structured proforma. Statistical analysis was done in Microsoft Excel.

Results

The findings of exfoliative cytology of voided urine were correlated with the histopathological features. The age ranges from 16 years to 110 years. The mean age was 58.4± SD14.9 years. Out of 100 cases, the maximum number (49 cases; 49%) of patients belonged to the age group 51-70 years. The male-to-female ratio was 5:1 (approximately). So, the study points to male preponderance in urinary bladder mass. 55% of patients were from low socioeconomic status and 71% of patients were smokers.

Table I. Cytomorphological findings from voided urine in 100 cases.

Cytological diagnosis	Frequency n (%)
Negative for malignancy	17 (17)
Reactive	10 (10)
Atypical	00 (00)
Suspicious for malignancy	10 (10)
Positive for malignancy	63 (63)
Unsatisfactory	00 (00)
Total	**100 (100)**

At the time of the first consultation, 78 (78%) patients had hematuria. Along with hematuria, 63 (63%) had frequency and urgency. 22 (22%) patients had complained of urgency and dysuria without hematuria. The most commonly located urinary bladder masses were in the lateral wall which is about 53 (50%) cases, 19 (19%) were in the posterior wall, 15 (15%) were in the neck, 10 (10%) were in the trigone and 03 (3%) were in the anterior wall. For histopathology, 98% of the biopsy sample were transurethral resection of bladder tumor (TURBT) and the rest were cystectomy specimens. Muscularis propria was present in 60 (60%) biopsy samples. Cytomorphological findings of 100 cases showed, 63% was positive for malignancy; 10% of cases were reported as suspicious for malignancy (table I), and 27% of case was reported as negative. All suspicious diagnoses were included with the "positive" diagnoses because the patients were ultimately proven to have transitional cell carcinoma by histopathological examination (Figure 1). No cases had atypical cells in the smear or were unsatisfactory for reporting.

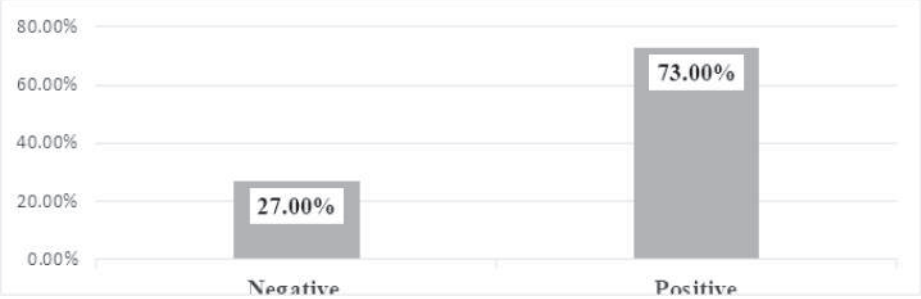

Figure 1: Cytomorphological findings from voided urine in 100 cases.

Based on histopathology, 76% of the case was diagnosed as papillary urothelial carcinoma followed by adenocarcinoma, metastatic squamous cell carcinoma, leiomyosarcoma, and sarcoma botryoides 1 (1%) case in each (figure 02). The rest of the cases were negative for malignancy. Among papillary urothelial carcinoma, 53 (53%) were of high grade.

Table II. Cyto-histopathological correlation.

Histological diagnoses	Frequency n (%)	Cytological diagnoses	
		Positive n (%)	Negative n (%)
Papillary urothelial carcinoma (low grade)	23 (23)	15 (65)	8 (35)
Papillary urothelial carcinoma (high grade)	53 (53)	53 (100)	0 (0)
Adenocarcinoma	1 (1)	1 (100)	0 (0)
Metastatic squamous cell carcinoma	1 (1)	1 (100)	0 (0)
Leiomyosarcoma	1 (1)	1 (100)	0 (0)
Sarcoma botryoides	1 (1)	0 (0)	1 (100)
Cystitis glandularis	7 (7)	0 (0)	7 (1)
Cystitis cystica	3 (3)	0 (0)	3 (100)
Polypoid cystitis	6 (6)	1 (20)	5 (80)
Follicular cystitis	2 (2)	0 (0)	2 (100)
Interstitial cystitis	2 (2)	1 (50)	1 (50)

Table III. Cyto-histopathological correlation of invasive malignant tumors.

Histological diagnoses	Frequency n (%)	Cytological diagnoses	
		Positive n (%)	Negative n (%)
Invasive papillary urothelial carcinoma	51 (92.8)		
Low grade	6 (10.9)	6 (100)	0 (0)
High grade	45 (81.9)	45 (100)	0 (0)
Invasive adenocarcinoma	1 (1.8)	1 (100)	0 (0)
Leiomyosarcoma	1 (1.8)	1 (100)	0 (0)
Sarcoma botryoides	1 (1.8)	0 (0)	1 (100)
Metastatic Squamous cell Carcinoma	1 (1.8)	1 (100)	0 (0)
Total	**55 (100)**	**54 (98.18)**	**1 (1.82)**

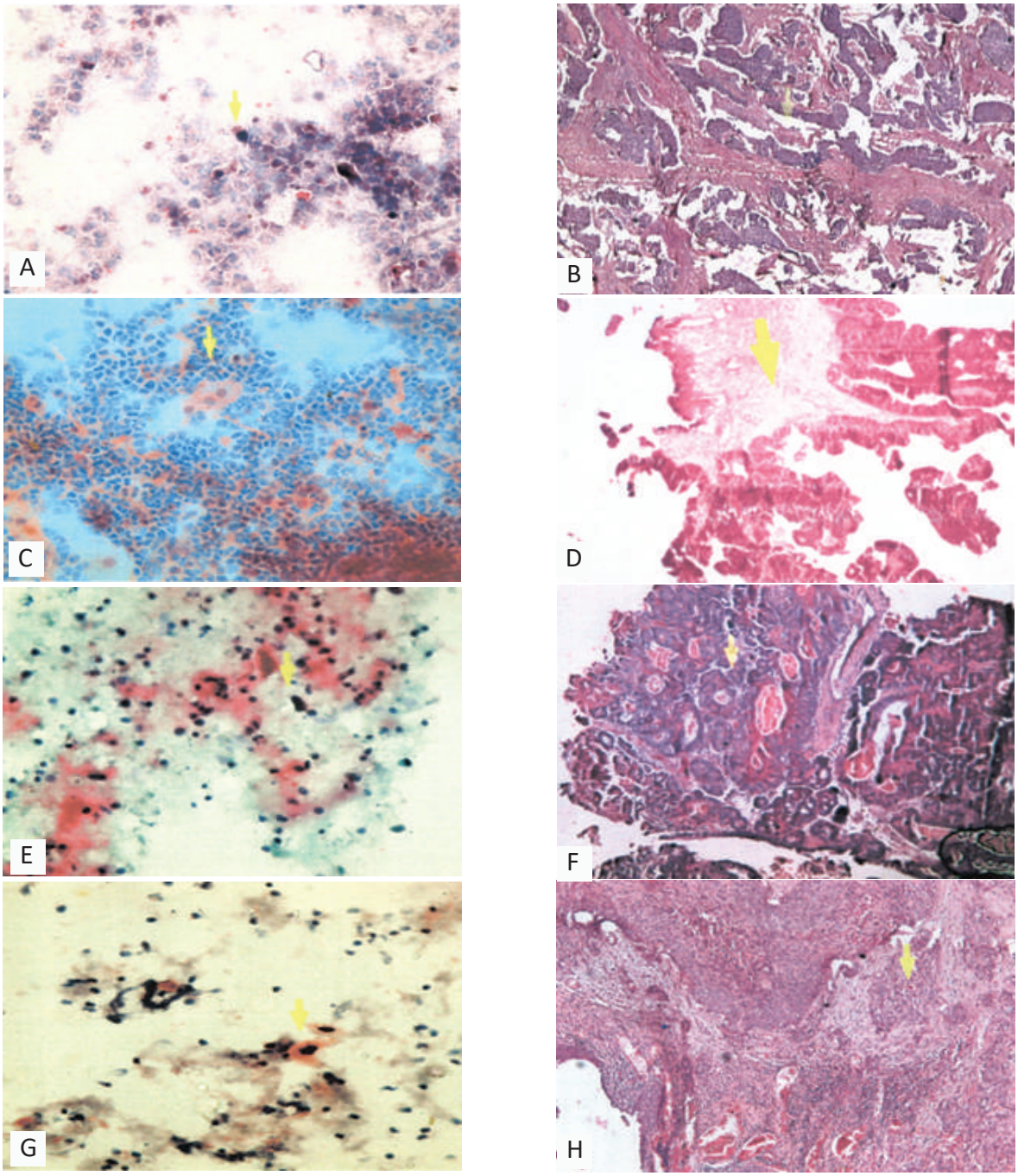

Figure 2: Photomicrographs (400X) of different variants of Urinary bladder cancer. A+B) Cytology of papillary urothelial carcinoma, high grade (A); histopathology sections of the same case in B. C+D) Clusters of normal urothelial cells in cytology (C), whereas histopathology of the same case showed papillary urothelial carcinoma, low grade (D). E+F) Adenocarcinoma in cytological smears and histopathological sections respectively. G+H) Squamous cell carcinoma in cytological smears and histopathological sections respectively. (Papanicolaou stain and Hematoxylin and Eosin stain (H & E) were used in cytopathology and histopathology respectively. Yellow arrows direct tumor cells.)

Table IV. Diagnostic performance of urine cytology to detect malignancy concerning histopathology .

Urine cytology	Malignant	Inflammatory condition	Total
Positive	71 (TP)	02 (FP)	73
Negative	09 (FN)	18 (TN)	27
Total	80	20	100

Out of 80 histologically diagnosed malignant cases, 71 were diagnosed as positive for malignant cells and nine were negative for malignant cells by urine cytology (table II). In the present series, 55 (55%) malignant tumors were invasive. Except for one, all the invasive cases gave positive cytologic results. One case of sarcoma botryoides could not be detected by urine cytology (table III). Out of 20histologically diagnosed inflammatory conditions, two were diagnosed as positive for malignant cells and 18 were diagnosed as negative for malignant cells by urine cytology. This study showed that the sensitivity and specificity of exfoliative urine cytology in the diagnosis of urinary bladder tumor were 88.8% and 90.0% respectively. The positive prediction value (PPV) of exfoliative urine cytology in predicting urinary bladder tumors among the test-negative subjects was 97.3% and the negative predictive value (NPV) among the test-negative subjects was 66.7%. The percentage of false negatives was 11.3% in urine cytology. The percentage of false positives was 10%. The accuracy of the diagnosis of urinary bladder tumors by exfoliative urine cytology was 89%.

Discussion

The practical importance of urine cytology is, first to reduce the chance of biopsy sampling error and second, the detection of cancer in patients who refuse frequent cystoscopic procedures. Urine cytology before review cystoscopy may help in avoiding unnecessary intervention and reduce both cost and patient morbidity [15]. Since 50-70% of the patients with urothelial carcinoma particularly the superficial form usually experiences a recurrent tumor, it is important to have a non-invasive technique that can predict the likelihood of recurrence of bladder cancer [16]. Urinary cytology can detect the most aggressive neoplasm as well as carcinoma in situ [8]. In this study, clinically and/or ultrasonographically suspected 100 patients of urinary bladder mass were evaluated to observe the performance of the exfoliative cytology of voided urine based on histopathology. The age ranges from 16 years to 110 years with a mean±SD of 58.4±14.9 years. Maximum number (31 cases; 31%) of patients belonged to age group 61-70 years. The male-to-female ratio was 5:1 (approximately). Some studies reported that bladder cancer is more frequent in male patients above 60 years of age [17-19]. Regarding etiological factors, cigarette smoking has a clear influence which increases the risk of bladder cancer 3-7-fold, and it has been estimated that 50-80% of bladder cancers among men can be attributed to the use of cigarette smoking [4]. In this study, there were 71 (71%) smokers and 29 (29%) were non-smokers which is in concordance with that study. In a developing country like ours, though no specific cause is yet identified, environmental factors like the use of pesticides should be taken into consideration as a possible causative factor for bladder carcinogenesis. Hematuria was the commonest presenting symptom in this study and 78 (78%) patients presented with hematuria. Several previous studies also showed that 80% of bladder cancer patients presented with hematuria [20]. By cystoscopy, lateral wall involvement is the highest (53%) than other locations in the present study. A recent study on 1000 cases, reported that the lateral wall was the most common site for

bladder cancer [21]. In the present study, voided urine cytology was done individually for each patient. All suspicious cases were included with the "positive" diagnoses. Considering that diagnoses became positive in 73 (73%) cases and negative in 27 (27%) cases. Subsequently, all TURBT specimens and two cystectomy specimens underwent histopathology. Papillary urothelial carcinoma was found in 76 (76%) cases, followed by adenocarcinoma, and metastatic squamous cell carcinoma. leiomyosarcoma and sarcoma botryoides 1 (1%) in each case. Several recent studies showed that histopathologically more than 80% of bladder cancer was papillary urothelial carcinoma [22]. These findings were similar to this study. In the present study, out of 100 cases, 53 (53%) were of high-grade papillary urothelial carcinoma and 23 (23%) were of low-grade papillary urothelial carcinoma. In the rest 04 (04%) cases grading was not done because these were malignant tumors other than papillary urothelial carcinoma. The remaining 20 cases were inflammatory conditions of the urinary bladder. Among the papillary urothelial carcinomas of low-grade variety 15 (65%) cases were cytologically reported as positive for malignant cells and 08 (35%) were reported negative for malignant cells (Figure: 02). In contrast all the high-grade lesions were identified correctly by cytology in voided urine in the present study. Comparative study regarding cyto-histologic correlation in previous studies is in concordance with the present study [23]. The limitations of urine cytology in low-grade papillary urothelial carcinomas are due to individual cells shaded in voided urine may not be significant for the diagnosis of cancer. So, well-differentiated tumors are not readily detected cytologically but results improve with higher-grade [11]. So positive cytology presumably identifies patients with high-grade lesions. Consistent with previously published data, this study showed the highest diagnostic accuracy with high-grade tumors and the lowest with low-grade tumors. When correlation between histopathological and cytologic diagnoses was done, it was observed that invasive tumors of all grades gave more consistent positive cytologic results. Among the total 80 cases of malignant tumors (all types), 55 (55%) cases were invasive in nature. They invaded muscularis propria. Except for one, all the invasive cancers gave positive cytologic results in the present study. Only one case of sarcoma botryoides could not be detected by urine cytology. The sensitivity, specificity, and overall accuracy of exfoliative urine cytology in the diagnosis of urinary bladder tumors were high. These values are concordant with several previous studies [24]. Positive cytology correlates well with grade, stage, and prognosis of bladder tumors, so it can be used in the detection, diagnosis, and follow-up of the primary tumor and for recurrent tumors receiving therapy [25]. In the present study, there were 2 (10%) false positive cases. In those cases, where urine cytology shows high-grade malignant cells but histopathological diagnosis reveals an inflammatory condition, the conclusion will be that besides the inflammatory condition, there might be high-grade abnormality within the bladder not detected during cystoscopic removal. A tumor localized within a diverticulum or higher up the tract may escape detection during cystoscopy but urine cytology can give a meaningful diagnosis in such cases if the tumor is of high grade. The possibility should be kept in mind and a thorough search should be made to detect the lesions. Moreover, urine cytology has the advantage of sampling whole bladder mucosa. So, invasive diseases or flat malignant lesions can be diagnosed long before identification by ultra-sonogram or cystoscopy and thus help in increasing the survival rate of the patients.

Conclusion

Cytologic studies of voided urine are useful for the detection of urothelial tumors and for follow-up of treated bladder cancer patients. The main advantage of urine cytology is that it can detect the cancer before it progresses to invasive disease. In a developing country like Bangladesh where facilities for cystoscopy and other relevant investigations are not available practically in most rural institutions, urine cytology can prove to be a simple non-invasive valuable tool in the detection, diagnosis, and follow-up of patients with primary and recurrent urinary bladder tumors.

References

1. Parkin DM. Pisani P. Ferlay J. Global cancer statistics. Ca Cancer J Clin. 1999 Jan; 49(1):33-64.
2. Madeb R, Golijanin D, Knopf J, Messing EM. Current state of screening for bladder cancer. Expert Review of Anticancer Therapy. 2007 Jul 1; 7(7):981-7.
3. Kirkali Z, Chan T, Manoharan M, Algaba F, Busch C, Cheng L, Kiemeney L, Kriegmair M, Montironi R, Murphy WM, Sesterhenn IA. Bladder cancer: epidemiology, staging and grading, and diagnosis. Urology. 2005 Dec 1; 66(6):4-34.
4. Epstein JI. The lower urinary tract and male genital system. Robbins and Cotran Pathologic Basis of Diseases. 2005.
5. Reuter VE. The pathology of bladder cancer. Urology. 2006 Mar 1; 67(3):11-7.
6. Audureau E, Karmaly M, Daigurande C, Paris C, Evreux E, Thielly P, Pfister C. Bladder cancer and occupation: a descriptive analysis in Haute Normandie in 2003. Progres en Urologie: Journal de L'association Francaise D'urologie et de la Societe Francaise D'urologie. 2007 Apr 1; 17(2):213-8.
7. Janković S, Radosavljević V. Risk factors for bladder cancer. Tumori Journal. 2007 Jan; 93(1):4-12.
8. Dinney CP, McConkey DJ, Millikan RE, Wu X, Bar-Eli M, Adam L, Kamat AM, Siefker-Radtke AO, Tuziak T, Sabichi AL, Grossman HB. Focus on bladder cancer. Cancer cell. 2004 Aug 1; 6(2):111-6.
9. Pashos CL, Botteman MF, Laskin BL, Redaelli A. Bladder cancer: epidemiology, diagnosis, and management. Cancer practice. 2002 Nov; 10(6):311-22.
10. Burchardt M, Burchardt T, Shabsigh A, De La Taille A, BENsON MC, Sawczuk I. Current concepts in biomarker technology for bladder cancers. Clinical chemistry. 2000 May 1; 46(5):595-605.
11. Koss LG. Tumor of the urinary tract in urine and brushings. Koss's Diagnostic Cytology. 2006.
12. Koss LG, Melamed MR, editors. Koss' diagnostic cytology and its histopathologic bases. Lippincott Williams & Wilkins; 2006.
13. Kannan V, Bose S. Low grade transitional cell carcinoma and instrument artifact. A challenge in urinary cytology. Acta cytologica. 1993 Nov 1; 37(6):899-902.
14. Porter MP, Penson DF. Health related quality of life after radical cystectomy and urinary diversion for bladder cancer: a systematic review and critical analysis of the literature. The Journal of urology. 2005 Apr 1; 173(4):1318-22.
15. Toivonen T, Hästö AL. Large-volume cytocentrifuge for processing alcohol-fixed cytologic specimens. Application in urinary cytology. Acta cytologica. 1991 May 1; 35(3):269-72.
16. Giella JG, Ring K, Olsson CA, Karp FS, Benson MC. The predictive value of flow cytometry and urinary cytology in the followup of patients with transitional cell carcinoma of the bladder. The Journal of urology. 1992 Aug 1; 148(2):293-6.
17. Herr HW, Badalament RA, Amato DA, Laudone VP, Fair WR, Whitmore Jr WF. Superficial bladder cancer treated with bacillus Calmette-Guerin: a multivariate analysis of factors affecting tumor progression. The Journal of urology. 1989 Jan 1; 141(1):22-8.
18. Cowan DF, Wu B, Young GP, Khanna OP. Correlation of histopathological, cytological and flow cytometric findings in neoplastic and nonneoplastic lesions of the bladder. The Journal of urology. 1987 Oct 1; 138(4):753-7.
19. Cheng L, Darson M, Cheville JC, Neumann RM, Zincke H, Nehra A, Bostwick DG. Urothelial papilloma of the bladder: clinical and biologic implications. Cancer. 1999 Nov 15; 86(10):2098-101.
20. Raab SS, Lenel JC, Cohen MB. Low grade transitional cell carcinoma of the bladder. Cytologic diagnosis by key features as identified by logistic regression analysis. Cancer. 1994 Sep 1; 74(5):1621-6.
21. Santos LL, Amaro T, Pereira SA, Lameiras CR, Lopes P, Bento MJ, Oliveira J, Criado B, Lopes CS. Expression of cell-cycle regulatory proteins and their prognostic value in superficial low-grade urothelial cell carcinoma of the bladder. European Journal of Surgical Oncology (EJSO). 2003 Feb 1; 29(1):74-80.
22. Hughes JH, Raab SS, Cohen MB. The cytologic diagnosis of low-grade transitional cell carcinoma. Pathology Patterns Reviews. 2000 Nov 1; 114(suppl_1):S59-67.
23. Oosterlinck W, Solsona E, Akaza H, Busch C, Goebell PJ, Malmström PU, Özen H, Sved P. Low-grade Ta (noninvasive) urothelial carcinoma of the bladder. Urology. 2005 Dec 1; 66(6):75-89.
24. David KA, Mallin K, Milowsky MI, Ritchey J, Carroll PR, Nanus DM. Surveillance of urothelial carcinoma: stage and grade migration, 1993–2005 and survival trends, 1993–2000. Cancer: Interdisciplinary International Journal of the American Cancer Society. 2009 Apr 1; 115(7):1435-47.
25. Frable WJ, Paxson L, Barksdale JA, Koontz Jr WW. Current practice of urinary bladder cytology. Cancer Research. 1977 Aug 1; 37(8_Part_2):2800-5.